

# STUDY ON THE OUTCOME OF ENDOSCOPIC TYMPANOPLASTY VERSUS THE CONVENTIONAL METHOD

**Authors:** Deepalakshmi Thantry (1), Gururaj Thantry (2) Rajeshwari Shastri (3) Chitra. R.S.\*(4)

**Authors Affiliations:** (1) Associate Professor, Department of ENT (2) Professor, Department of Anesthesia, AJIMS, Mangalore (3) Associate Professor, Department of Pharmacology, Kasturba medical college, Mangalore, (4) Post Graduate, Department of ENT, AJIMS, Mangalore

## ABSTRACT

### BACKGROUND

Endoscopic tympanoplasty is a minimally invasive surgery for the repair of tympanic membrane with complete graft survival and hearing outcomes to the conventional microscopic surgery.

This study was aimed to evaluate the success rate of endoscopic trans-canal closure of tympanic membrane perforation compared to the conventional post auricular approach using temporalis fascia and tragal cartilage as a graft.

### METHODS

Our study consisted of 50 patients with chronic otitis media, with dry ear for last 2 months and all patients were between 18-50 yrs of age. All selected patients were subjected to pre-operative oto-endoscopic and audiological assessment and underwent endoscopic trans-canal tympanoplasty using temporalis fascia in some and tragal cartilage in some.

### RESULTS:

Trans-canal endoscopic surgery resulted in the successful healing of 97% whereas in the conventional method successful healing was only up-to 92%. The average hearing gain was also significantly improved in endoscopic surgery compared to that of the conventional method. When the operative time was considered, the mean time in the endoscopic method was lesser. All patients were followed up for a period of 3 months.

## CONCLUSION:

Comparisons between these 2 groups focused on the surgical outcomes and restoration of hearing, including the duration of surgery. All patients were followed up for a period of 3 months.

Using this method not only improves the cosmetic outcome but also reduces the post-operative morbidity with shorter operative time.

## KEYWORDS

Endoscopic Tympanoplasty, Conventional Tympanoplasty, Tympanoplasty

## INTRODUCTION

Since the introduction of tympanoplasty in the 1950s, a variety of graft materials and surgical techniques have been developed and used to close perforations in the tympanic membrane (TM). Temporalis fascia and perichondrium remain the most widely used materials, and successful closure can be achieved in 80% to 90% in patients who undergo primary tympanoplasty with a microscopic approach. In some cases, postauricular skin incisions and soft tissue dissections are mandatory during tympanoplasty using a microscope. Conventional microscopic tympanoplasty with a postauricular incision remains the most effective procedure for patients with chronic otitis media, especially in cases of anterior or large TM perforation as well as anterior bony overhang. This conventional procedure results in surgical scar and significant pain to the patient.

Minimally invasive otologic surgery has recently been developed along with endoscopic techniques. Endoscopic ear surgery, first tried in the 1990s, has become popular with anatomic and physiologic concepts. Advantages of endoscopic ear surgery compared to the conventional microscopic surgery include avoiding endaural vertical and postauricular incisions, and mastoidectomies in securing the surgical view. Endoscopically, the typical transcanal approach is possible by elevating a tympanomeatal flap. This avoids other unnecessary incisions and soft tissue dissections. The endoscopic approach also provides better visualization of hidden areas in the middle ear cavity including the anterior and posterior epitympanic spaces, sinus tympani, facial recess, and hypotympanum. Endoscopy-mediated procedures can decrease residual cholesteatomas and recurrences during surgeries for cholesteatoma removal. The value of endoscopes combined with the conventional microscopic eradication of cholesteatoma has been well established. Besides surgeries for cholesteatoma removal, an exclusively endoscopic approach during tympanoplasty has been applied to facilitate minimally invasive surgery.

However, endoscopic surgery has several disadvantages. Only one-hand surgery is feasible with the endoscopic technique, which is less efficient; in a situation of massive bleeding, the endoscopic view could be stained by blood and continuing the procedure could be difficult. Furthermore, endoscopic instrument could make direct injury and thermal damage by light source. There has been lack of reliable data regarding the efficacy and functional outcome of endoscopic tympanoplasty as compared with conventional microscopic tympanoplasty. In this study, we evaluate and compare the results of hearing outcome, postoperative pain assessment, operation time, graft success rate, and surgical complications in patients who underwent endoscopic and conventional microscopic tympanoplasty.

## AIM

The aim is to compare the clinical benefits of endoscopic tympanoplasty compared to conventional microscopic surgery by an endaural or postauricular approach using temporalis fascia or tragal cartilage as a graft material.

## MATERIALS AND METHODS

This is a prospective clinical study which was conducted in the Department of Otorhinolaryngology at AJIMS, Mangalore Karnataka from March 2021– December 2021

## SUBJECTS

- (1) The study enrolled 50 patients aged 18 to 50 years (mean,  $33.0 \pm 16.5$  years) who underwent tympanoplasty type I for chronic otitis media at AJIMS from March to December 2021.
- (2) All patients had endoscopic examination, pure tone audiometry, and temporal bone computed tomography as preoperative work-up and had postoperative follow-up with endoscopic examination and pure tone audiometry at 3 months after surgery.
- (3) Mean follow-up was 6.4 months (range : 3 to 11 months).
- (4) Patients were classified into two groups according to type of surgery: endoscopic tympanoplasty (ET) and microscopic tympanoplasty (MT).

## METHODS

- Pure tone audiometry tests were performed at preoperatively and 3 months postoperatively. Hearing thresholds including air conduction and bone conduction were measured at 0.5, 1.0, 2.0, and 4.0 kHz, and the pure tone averages were calculated.
- Detailed operative data were collected including type of operation (ET, MT), operation time, whether external auditory canal (EAC) widening was performed for a better surgical view or not.
- Width of the narrowest portion of the EAC on the axial image of computed tomography

was measured.

- During the postoperative follow-up, pain scale score was collected immediately after surgery, at 3 hours, and 1 day postoperatively. Pain scale was scored using an 11-item, patient-reported numeric rating scale of pain intensity (NRS-11, range 0 to 10).
- The graft success rate was also determined. Graft success as well as healing status of the EAC was evaluated at 3 months postoperatively by endoscopic examination. A dry, clean ear canal without TM perforation represented graft success.

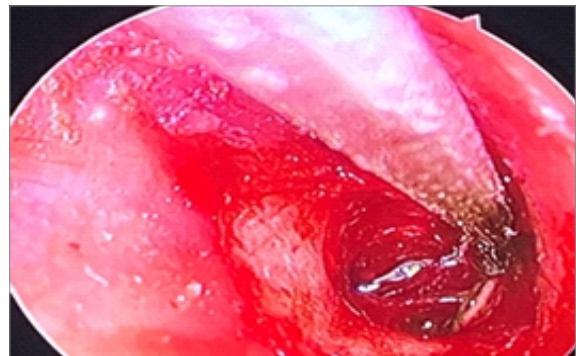
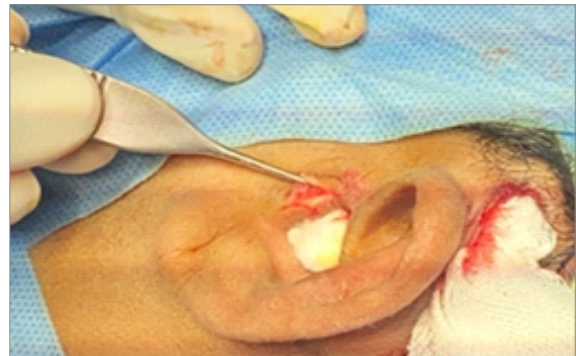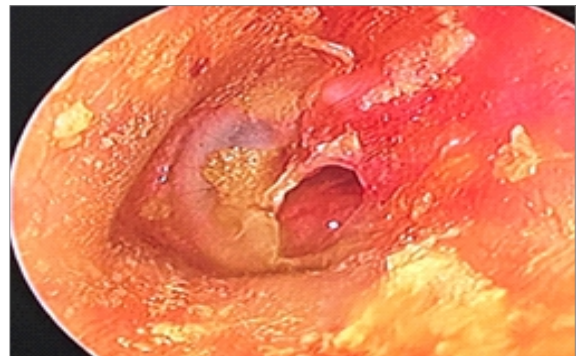
### **SURGICAL TECHNIQUE**

Tympanoplasty type I procedures were performed in all patients.

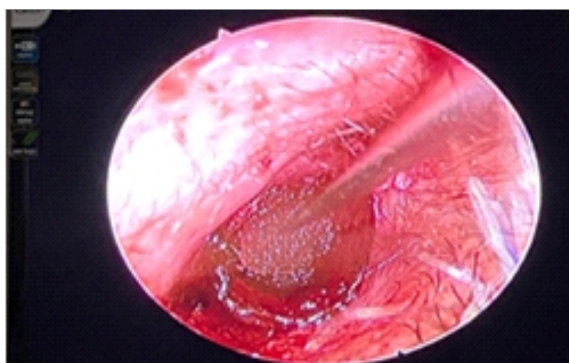
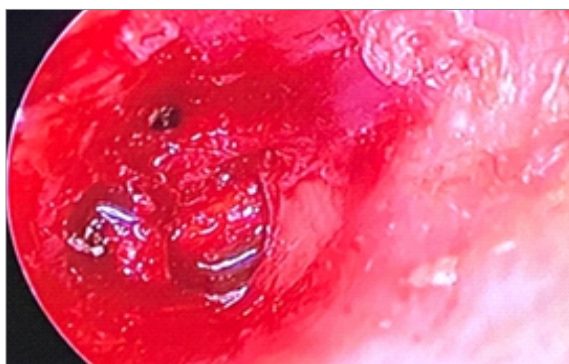
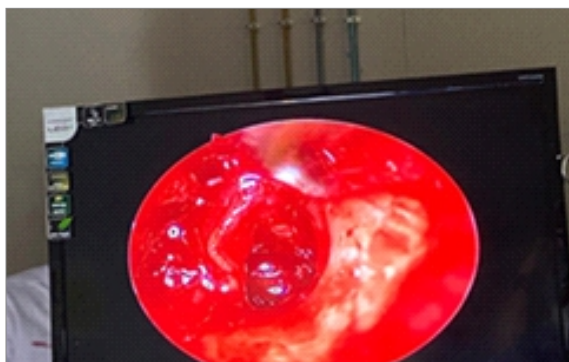
- The EAC was widened during the surgery when visualization of the middle ear cavity was difficult due to anterior bony overhang. In the MT group, Carl Zeiss microscope was used, and detailed procedures were almost identical with the ET group.
- In the MT group, surgery was performed with an endaural incision, based on the Lempert method. The first incision was made along the posterior half of the ear canal.
- The second vertical incision was made in the incisura to connect the first incision with the area between the tragus and the root of the helix.
- A postauricular incision was used in cases where the perforation margin was poorly visualized due to narrow external ear canal, anterior bony overhang, or large TM perforation.
- In the ET group, an endoscopic system (Karl Storz, Tuttlingen, Germany) and 0- or 30-degree rigid endoscopes (3.0- or 4.0-mm diameter, 11 or 16 cm long; Karl Storz) were used. In this technique, incisions were performed 5 to 6 mm lateral to tympanic annulus in the posterior part of the EAC perpendicular to the TM tympanic from the superior and inferior end of the first incision.
- A tympanomeatal flap was elevated for

middle ear cavity visualization, and pathologic processes of the middle ear were removed.

- The middle ear was packed with a Gelfoam and the autologous graft, which was most often harvested from tragal perichondrium and rarely temporalis fascia, was underlaid medial to the TM remnant and the manubrium of the malleus.
- Finally, the tympanomeatal flap was returned to its original position and the medial aspect of the ear canal was packed with pledgets of Gelfoam.







## RESULTS

- The demographic data and clinical findings of each group (ET, n=25; MT, n=25) and Mean age was  $33.0 \pm 16.5$  years. The ages did not differ significantly.
- Preoperative audiometric tests including bone and air conduction, and air-bone gap were not significantly different between the two groups.
- The TM perforation size was larger in ET (11.9%), without statistical significance.
- Mean operation time of the MT group ( $88.5 \pm 28.5$  minutes) was significantly longer than the ET group ( $65.2 \pm 20.1$  minutes).
- EAC width was shorter in the ET group ( $3.9 \pm 0.7$  mm) than in the MT group ( $4.3 \pm 0.6$

mm). However, EAC widening was not necessary in the ET group and was performed in 15.4% of patients in the MT group.

- Graft success rate in the ET and MT group was 100% and 92.8%, respectively.
- Pain scale scores were compared between the three groups immediately after surgery, 3 to 6 hours later, and 1 day postoperatively. Immediately and 3 to 6 hours after surgery, pain scales were not significantly different. Pain scale score of 1 day after surgery was significantly lower in ET group. The ET group displayed  $0.4 \pm 1.0$  of pain score, and MT group was  $2.5 \pm 1.0$  at 1 day after surgery.
- Preoperative audiometric parameters including bone conduction, air conduction, and air-bone gap were not significantly different between ET and MT group. Pre- and postoperative air-bone gap was analyzed with paired t-test separately in each group. In the ET group, the pre- and postoperative air-bone gap was  $18.0 \pm 1.0$  dB and  $9.0 \pm 1.0$  dB, respectively, which was a significant improvement. The respective values in the MT group also represented a significant improvement.
- Bone conduction preoperatively and 3 months postoperatively were compared using the paired t-test in each group to evaluate inner ear damage. All groups had no significant difference between pre- and postoperative bone conduction.

In addition, 4.0 kHz bone conduction hearing levels were compared for sensitive evaluation of inner ear damage in each group.

- In the ET group, bone conduction hearing level was  $25.8 \pm 21.9$  dB preoperatively and  $28.2 \pm 20.3$  dB at 3 months postoperatively. There was no significant changes in the ET group. Otherwise, there was significant aggravation of bone conduction in the MT group. Preoperative bone conduction of the MT group was  $30.5 \pm 21.0$  dB and

---

---

postoperative bone conduction was  $37.4 \pm 22.8$  Db.

#### **LIMITATIONS:**

- Limitation of this study was that type of surgery (endoscopic or microscopic) was decided by each surgeon's preference and patient counselling which could cause bias.
- In addition, preoperative clinical data such as age, sex, hearing and size of TM perforation were compared, and they were not significantly different between two groups. Hence further well-designed randomized controlled trial is needed to overcome the bias.

#### **SUMMARY**

- The endoscopic technique had shorter operation time and has reduced pain level compared with microscopic tympanoplasty.
- Regardless of the perforation size, there was no need for external incision or EAC drilling in the ET group, which may lead to better patient satisfaction.
- For tympanoplasty, the endoscopic technique contributes to minimal invasive surgery with transcanal incision only. It could minimize additional incision, EAC widening for better surgical view, and especially postoperative pain.

#### **DISCUSSION**

Endoscopic ear surgery was first applied to cholesteatoma removal and myringoplasty. Indications are increasing and include middle ear tumour, ossiculoplasty, tympanoplasty, and cochlear implantation. Several meta-analyses and review articles of endoscopic ear surgery support the safety of the approach, with minimal morbidity evident. Since the endoscopic technique was introduced for middle ear surgery, the concept of minimally invasive surgery has developed. This could avoid mastoidectomies, external incisions, and soft tissue dissection in selected cases as compared with the conventional microscopic approach.

There are still many advantages of microscopic ear surgery. It provides binocular vision along with an excellent magnified surgical view. Using a microscope, two-hand surgery is possible, which is extremely useful to remove blood from the operation field. However, visualization of deep and hidden spaces involving sinus tympani, epitympanum, facial recess, and the attic area are limited with a microscope.

Therefore, microscopic techniques frequently need further soft tissue dissection/retraction and bony drilling to obtain a better surgical view. An endoscopic system allows surgeons a clear and high-definition surgical view, with less chance of incision and drilling, as the powerful light source is located at the tip of the endoscope, and angled lenses facilitate visualization of hidden recesses. In addition, endoscopic view could provide better chance of education to trainees.

In this study, EAC widening or external incision were not needed in any patient of ET group, although EAC width was significantly narrower in the ET group. Otherwise, one-third of patients who underwent microscopic tympanoplasty had EAC widening by drilling, and three-quarters of patients needed a postauricular incision. Patients who had microscopic postauricular tympanoplasty require postauricular incision care in the form of a compression bandage dressing and had more bloody oozing from the endaural operation site. No externally visible scars were created in the endoscopic group, which is a better cosmetic outcome that requires less postoperative care.

However, endoscopic ear surgery has several disadvantages as compared with microscopic technique. The endoscopic instrument can cause direct injury and thermal damage to the external canal and middle ear. Furthermore, only one-handed surgery is feasible with the endoscopic technique, which is less efficient; in a situation of massive bleeding, the endoscopic view could be hindered by blood and continuing the procedure could be difficult. The limitation of one-handed

surgery would likely be overcome by experience over time. Surgeons who skilled for microscopic surgery could be easily adapted to one-handed surgery with endoscopic system with short duration of learning curve improvement. Due to heat generation from light source of endoscope, recommended using submaximal light intensity, and frequent repositioning of the endoscope.

In this study, we assumed that there was no inner ear damage by light source, because bone conduction of endoscopic tympanoplasty patients was not significantly changed after surgery, and no patients experienced dizziness or nystagmus during postoperative period. In spite of the one-handed nature of the endoscopic surgery, the current data indicate that endoscopic tympanoplasty can be successfully performed by an experienced surgeon. Even in patients with large TM perforation or anterior bony overhang, endoscopic tympanoplasty was conducted and graft success rate was comparable to the microscopic group. The endoscopic group had significantly shorter operation time than the microscopic tympanoplasty group. Closure of the postauricular incision in the microscopic postauricular tympanoplasty group might extend the operation time. In addition, the endoscopic technique offered a wide and clean surgical view with minimal canal incision, which could result in minimal manipulation of soft tissue, bony drilling, and bleeding, and subsequently increased efficacy of surgery as well as reduced pain. Previous study also reported same results that operative time in endoscopic tympanoplasty was significantly shorter than microscopic tympanoplasty.

Studies have analyzed hearing outcome after endoscopic ear surgery. One study reported significant hearing improvements in pediatric patients after endoscopic tympanoplasty. Another study demonstrated significant hearing improvements after endoscopic middle ear

surgery for cholesteatoma removal. Similarly, significant improvements of air-bone gap after endoscopic tympanoplasty were found presently. The endoscopic system has been used for second-look procedures or primary resection of middle ear cholesteatoma. Advantages include clear observation of middle ear cavity, low recurrence rate, prevention of a retraction pocket, and preservation of ossicles. Presently, there were no patients with cholesteatoma, but we achieved a graft success rate of 100% at 3 months, with no recurrence of otorrhea at 3 months after endoscopic tympanoplasty.

Therefore, we suppose that the endoscopic technic could be helpful for eradication of pathologic processes in the middle ear, such as granulation tissue or adhesion, as well as cholesteatoma.

Little is known of postoperative pain after endoscopic ear surgery. Only one study reported that the endoscopic tympanoplasty gave an equal result to microscopic tympanoplasty regarding pain level. In that study, the endoscopic group had significantly lower level of pain than the microscopic groups 1 day after surgery. The reduced pain may reflect the lack of external incision as well as vertical endaural incision up to incisura and EAC bone drilling in the endoscopic technique.

## REFERENCES

1. Zollner F. The principles of plastic surgery of the sound-conducting apparatus. *J Laryngol Otol.* 1955 Oct;69(10):637–52. [PubMed] [Google Scholar]
2. Dornhoffer JL. Hearing results with cartilage tympanoplasty. *Laryngoscope.* 1997 Aug;107(8):1094–9. [PubMed] [Google Scholar]
3. Thomassin JM, Duchon-Doris JM, Emram B, Rud C, Conciatori J, Vilcoq P. Endoscopic ear surgery: initial evaluation. *Ann Otolaryngol Chir Cervicofac.* 1990;107(8):564–70. [PubMed] [Google Scholar]

- Scholar]
4. Marchioni D, Alicandri-Ciufelli M, Piccinini A, Genovese E, Presutti L. Inferior retrotympanum revisited: an endoscopic anatomic study. *Laryngoscope*. 2010 Sep;120(9):1880–6. [PubMed] [Google Scholar]
  5. Ayache S, Tramier B, Strunski V. Otoendoscopy in cholesteatoma surgery of the middle ear: what benefits can be expected? *OtolNeurotol*. 2008 Dec;29(8):1085–90. [PubMed] [Google Scholar]
  6. Migirov L, Shapira Y, Horowitz Z, Wolf M. Exclusive endoscopic ear surgery for acquired cholesteatoma: preliminary results. *OtolNeurotol*. 2011 Apr;32(3):433–6. [PubMed][Google Scholar]
  7. Thomassin JM, Korchia D, Doris JM. Endoscopic-guided otosurgery in the prevention of residual cholesteatomas. *Laryngoscope*. 1993 Aug;103(8):939–43. [PubMed] [Google Scholar]
  8. Good GM, Isaacson G. Otoendoscopy for improved pediatric cholesteatoma removal. *Ann OtolRhinolLaryngol*. 1999 Sep;108(9):893–6. [PubMed] [Google Scholar]
  9. Presutti L, Marchioni D, Mattioli F, Villari D, Alicandri-Ciufelli M. Endoscopic management of acquired cholesteatoma: our experience. *J Otolaryngol Head Neck Surg*. 2008 Aug;37(4):481–7. [PubMed] [Google Scholar]
  10. Badr-el-Dine M. Value of ear endoscopy in cholesteatoma surgery. *OtolNeurotol*. 2002 Sep;23(5):631–5.

**\*Corresponding Author:**

Dr. R.S. Chitra  
Post Graduate, Department of ENT,  
AJIMS, Mangalore

**How to cite this article**

Thantry D, Thantry G, Shastri R, Chitra. R.S. - Study  
On The Outcome Of Endoscopic Tympanoplasty

Versus The Conventional Method - UPJOHNS;  
December 2022;10(2) 14-20

DOI: <http://doi.org/10.36611/upjohns/volume10/Issue2/2>



This work is licensed under a Creative Commons  
Attribution 4.0 International License  
Copyright © 2020 –UPJOHNS